



Newsletter

2-year chondrotissue® follow-up by MRI and histology

— New JBJS article out now —

“Repair of a post-traumatic cartilage defect with a cell-free polymer-based cartilage implant” by J.M. Patrascu et al. has now been published in the August edition of the British Journal of Bone and Joint Surgery.

[Click here for download](#)

We have interviewed Dr. Jenel Patrascu from the Babes University of Timisoara, Romania, to discuss about his experience with the cell-free chondrotissue® cartilage implant and his newly published 2-year outcomes.

BioTissue: Dr. Patrascu, which indication have you treated with the cell-free chondrotissue® cartilage implant?

Dr. Patrascu: I implanted chondrotissue® in a 26 year old male patient with a posttraumatic cartilage defect of 6cm² and Outerbridge grade IV at the medial femoral condyle, which is no doubt a large sized defect. (Fig. 1)

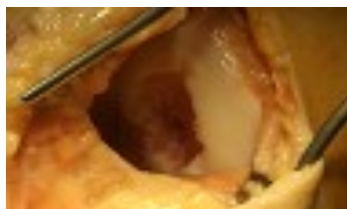

Fig. 1: opened and debrided 6cm² sized femoral cartilage defect

BioTissue: What results did you achieve? And how did you assess them?

Dr. Patrascu: 18 months after surgery I made a second-look arthroscopy to assess the quality of the cartilage repair tissue and the defect filling. Arthroscopic examination and MRI showed excellent volume filling of the 6cm² sized defect and cartilage repair tissue showed a firm integration into the

surrounding tissue. Also the histological repair evaluation by H&E staining revealed outstanding results and showed highly matured hyaline-like cartilage with round chondrocytic cells and chondron-like cell formation. (Fig.2, white arrows) 24 months after the surgery, the patient was free of pain and symptoms. He re-gained full knee function as assessed by KOOS before and 24 months after surgery. So he scored a KOOS of 100 in every sub-category compared to a KOOS 31 to 56 before surgery. We registered no signs of foreign body reaction, no infection, no inflammation nor allergic reactions.

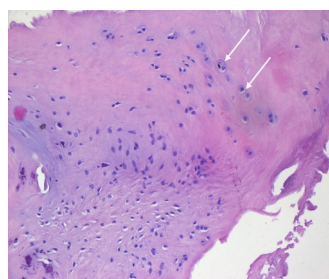


Fig. 2: histological evaluation of the repair tissue biopsy 18 months after surgery by H&E staining shows hyaline-like cartilage formation characterized by round chondrocytic cells and cluster formation (white arrows)

BioTissue: what can you tell from these promising results?

Dr. Patrascu: Today’s orthopaedics strive for a one-step cartilage treatment. It must be easy handling and proven by well-founded clinical outcomes. chondrotissue® unifies the advantages of the traditional microfracture technique to the structural and chondrogenic properties of a high-tech implant. Its stable texture also allows to easily fix chondrotissue® with secure standard techniques, which is a plus factor. My outcomes confirmed already published MRI findings and showed chondrotissue® to be effective in the treatment of large joint cartilage defects.